



A Comparison of Healing Effects of Propolis and Silver Sulfadiazine on Full Thickness Skin Wounds in Rats

E. Moghtaday Khorasgani*, A. H. Karimi and M. R. Nazem

Department of Pathology, Faculty of Veterinary Medicine, Islamic Azad University of Shahrekord, Shahrekord, Iran

*Corresponding author: E_moghtada@yahoo.com

ARTICLE HISTORY

Received: August 22, 2009

Revised: January 12, 2010

Accepted: January 19, 2010

Key words:

Bepanthane cream

Healing effects

Propolis

Rats

Silver sulfadiazine

Skin wounds

ABSTRACT

Healing effects of propolis and silver sulfadiazine (SS) on skin wounds in rats were compared using qualitative and quantitative parameters and histopathological findings. A total of 30 full thickness skin wounds were created on dorsal aspects of 10 rats; i.e., three wounds on each rat. Of these wounds, 10 each were allocated to group A (propolis), group B (SS) and group C (control). The skin wounds in the rats of groups A, B and C were covered daily for 14 days with 50% propolis cream, SS skin cream and bepanthane cream (control), respectively. Postoperatively, the wound surfaces were examined macroscopically and the healing process and the rates of wound expansion, contraction and epithelialization processes were quantitatively analyzed. As a result, propolis was found in general to have a better wound healing effect than others. At the 10th day of experiment histopathologically, there was inflammatory reaction with infiltration of lymphocytes, macrophages and neutrophils and proliferation of fibroblastic loose connective tissue in dermis of rats of all groups. The severity of these changes was lower in propolis treated group compared to other two groups.

©2010 PVJ. All rights reserved

To cite this article: Khorasgani EM, AH Karimi and MR Nazem, 2010. A comparison of healing effects of propolis and silver sulfadiazine on full thickness skin wounds in rats. Pak Vet J, 30(2): 72-74.

INTRODUCTION

Propolis is a natural resin produced by bees, to build their hives. It is made from the buds of conifer and poplar trees, beeswax, and other bee secretions. The Assyrians used propolis to heal wounds and tumors, while the Egyptians used it for mummification (Kartal *et al.*, 2003). Today, propolis is commonly found in chewing gum, cosmetics, creams, lozenges and skin creams. It is frequently used in foods and beverages with the claim that it can maintain or improve health (Kooa *et al.*, 2000) and has anti-viral (Kartal *et al.*, 2003), anti-inflammatory and immuno-stimulatory (Khayyal *et al.*, 1993) effects. Additional studies have shown propolis to be tumoricidal, antifungal, antiamebic and antipyretic (Grunberger *et al.*, 1980; Park *et al.*, 1998). It has also been found to have therapeutic effect on wound healing (Kartal *et al.*, 2003). Silver sulfadiazine (SS) is the topical agent and is also used universally today in wound healing (Altman *et al.*, 1990). The purpose of this study was to compare healing rates of wounds treated with propolis or silver sulfadiazine in a rat model.

MATERIALS AND METHODS

The dorsal aspects of 5 male and 5 female rats were clipped and prepared for aseptic surgery. All rats were

anesthetized with intramuscular administration of 5mg. kg⁻¹ xylazine hydrochloride (Rompun, Bayer) and 40 mg.kg⁻¹ ketamine hydrochloride (Ketanex-AIke). On each animal, two cranially and one caudally located square (4 cm) full-thickness skin wounds were created using a template prepared from an X-ray film. These wound sites were allocated to three groups (A, B and C) and covered with 50% propolis cream, silver sulfadiazine (SS) skin cream and bepanthane cream (control), respectively. Bepanthane cream was selected as it has protective role in skin healing. These applications were repeated daily for 14 days.

The wound boundaries were traced on a transparent sheet, scanned and the areas of wound sites and epithelialization fronts were measured with the help of the paint brush (PB) computer program. The data obtained were used to calculate area of the wound as described below (Kilic *et al.*, 2002):

Area (cm²) = P/K.M, where

P = Value of a particular wound site obtained on the PB,
K = A rate constant for expressing the value of PB as cm²,
M = Magnitude of tracings after scanning.

During the examination, the day wound contraction started, the rate of wound contraction, the day of epithelialization and the number of days in which wound healed fully were recorded.

On day 4, 7 and 14 post operations, the rats of all groups were euthanized and the skin tissue biopsy samples were collected for histopathological examination. The samples were fixed in 10% neutral buffered formalin, cut into 5 μ m thick sections, stained with hematoxylin and eosin (H&E), and examined microscopically (Grunberger *et al.*, 1980; Kiliç *et al.*, 2002). Numerical grading for histological assessment of severity of inflammation (1-4), epithelialization (1-3) and granulation (1-3) was carried out. Data thus collected were analyzed statistically through analysis of variance, using completely randomized design. Duncan's multiple range tests was applied for multiple means comparisons.

RESULTS

No mortality was seen in the animals of any group during the study. Macroscopically, in all treatment groups, no difference was seen with regard to inflammatory response i.e., heat, redness, and swelling. All wound sites healed completely within 17 days after surgery. On day 4 and 14 post treatment, no difference was seen in size of wound among three groups. However, on day 7, wound size in propolis treated group was less than other two groups ($P < 0.05$), the difference between latter two groups was non-significant (Table 1). Histologically, inflammatory reaction was significantly ($P < 0.027$) less and epithelialization was greater in propolis group as compared to control group (Table 2). There was no difference in granulation among rats of three groups.

Table 1: Changes in wound size (cm^2) in control, propolis and silver sulfadiazine treated groups during the healing period

Groups	Days of operation		
	4	7	14
Control	$3.7 \pm 0.2a$	$1.3 \pm 0.2a$	0.5 ± 0.2
Propolis	$3.2 \pm 0.3ab$	$0.1 \pm 0.1b$	0.1 ± 0.4
Sulfadiazine	$3.5 \pm 0.1a$	$1.2 \pm 0.1a$	0.5 ± 0.1

Values with different letters within a column differ significantly ($P < 0.05$).

Table 2: Histological findings among control, propolis and silver sulfadiazine treated groups

Groups	Parameters		
	Inflam-mation	Epitheliali-zation	Granula-tion
Control	$2.80 \pm 0.63a$	$1.10 \pm 0.31a$	1.20 ± 0.42
Propolis	$1.87 \pm 0.83b$	$1.25 \pm 0.46b$	1.20 ± 0.44
SS	$2.00 \pm 0.21ab$	$2.00 \pm 0.24c$	1.60 ± 0.57

Values with different letters within a column differ significantly ($P < 0.05$).

At the 7th day of experiment histopathologically, there was inflammatory reaction with infiltration of lymphocytes, macrophages, neutrophils and fibroblastic loose connective tissue in dermis of all groups. However, the severity of the reaction in propolis treated group was lower than other two groups. In control group, inflammatory cells were abundant and completely filled the gap of wound. Connective tissue between the wound

margins and surface debris were also more voluminous in control and SS treated groups than propolis treated group.

At the 14th day of experiment, the epithelial and dermal healing was complete in propolis group compared to control and SS groups. Both dermis and epidermis were completely regenerated in this group (Fig. 1). The appearance of the skin was normal except for the decreased epidermal thickness. In SS and control groups, the surface was covered by scab and epidermal regeneration was not completed. In control group, dermal and epidermal regeneration was also retarded as compared to SS and propolis groups (Figs. 2 and 3).

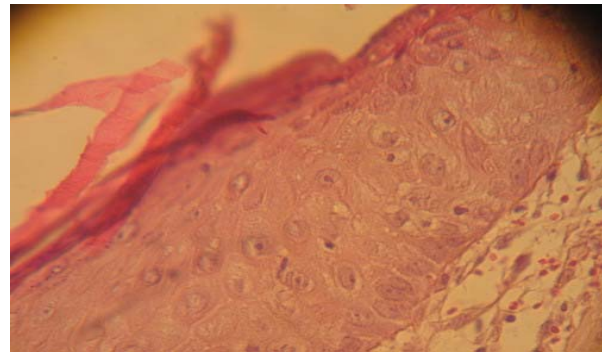


Fig. 1: Complete dermal and epidermal regeneration characterized by full thickness of epithelial covering on day 14 (Propolis group, H & E, 400 X).

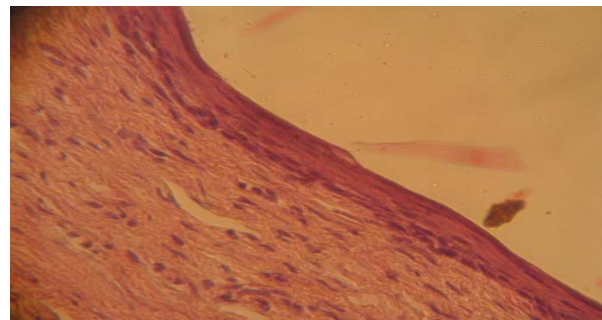


Fig. 2: Complete dermal and incomplete epidermal regeneration with surface debris on day 14 (SS group, H & E, 400 X).

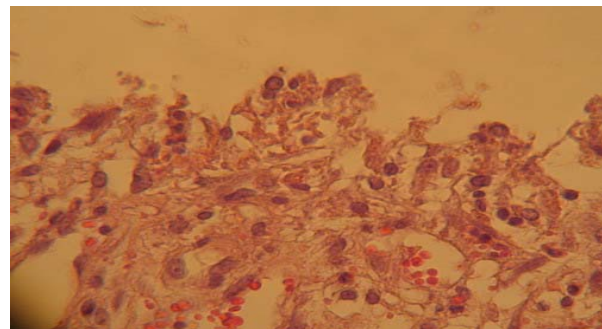


Fig. 3: Incomplete dermal and epidermal regeneration characterized by capillary proliferation and crust formation on day 14 (Control group, H & E, 400 X).

DISCUSSION

The wound healing process involves many complex factors. These may be classified as local factors, systemic factors and organ and species variability in response to injury. Topical medications should provide a specific desired effect during the appropriate stage of healing (Park *et al.*, 1998).

In this study, all wound sites healed in 17 days after surgery. The wound contraction and wound healing rates for propolis were higher than other groups. According to the results of the present study based on macroscopical, qualitative, and microscopical analyses, propolis has a higher healing performance than other drugs.

Propolis is a natural drug that has been employed extensively since ancient times (Kooa *et al.*, 2000; Nagaia and Sakai, 2001; Kılıç *et al.*, 2002). Khayyal *et al.* (1993) reported that aqueous propolis extract possessed significant anti-inflammatory properties and successfully reduced oedema in both acute and chronic models of inflammation. Bioflavonoids also boost immunity, the white blood cells, or lymphocytes are stimulated to produce interferon. Allergies are also subdued. Propolis also stimulates the thymus, the master gland of the immune system. The propolis skin cream appears to have beneficial effects on burn wounds (Subrahmanyam, 1998; Nagaia and Sakai, 2001; Gracia, 2001), inflammation of the skin and other skin lesions (Kooa *et al.*, 2000; Kartal *et al.*, 2003). It can be concluded from the present study that propolis skin cream appears to have beneficial effects on healing wounds in rats.

REFERENCES

- Altman M, C Suleskey, R Delisle and M DeVelasco, 1990. Silver sulfadiazine and hydrocortisone cream 1% in the management of phenol matricectomy. *J Am Padiatric Med Assoc*, 80: 545-547.
- Gracia CG, 2001. An open study comparing topical silver sulfadiazine and topical silver sulfadiazine–cerium nitrate in the treatment of moderate and severe burns. *Burns*, 27: 67-74.
- Grunberger D, R Ganarjee and K Eisinger, 1980. Preferential cytotoxicity on tumor cells by caffeic acid phenethyl ester isolated from propolis. *Experientia*, 44: 230–232.
- Kartal M, S Yıldız and S Kaya, 2003. Antimicrobial activity of propolis samples from two different regions of Anatolia. *J Ethnopharmacol*, 86: 69-73.
- Khayyal MT, MA El-Ghazaly and AS El-Khatib, 1993. Mechanism involved in the antiinflammatory effect of propolis extract. *Drug Exp Clin Res*, 19: 197-203.
- Kılıç S, N Timurkaan and S Unsaldı, 2002. Comparison of effects of some wound healing materials on full thickness skin wounds in rabbits. *Turkish J Vet Anim. Sci.*, 26: 263-272.
- Kooa H, BP Gomesa and PL Rosalen, 2000. *In vitro* antimicrobial activity of propolis and *Arnica montana* against oral pathogens. *Arch Oral Biol*, 45: 141-148.
- Nagaia T and M Sakai, 2001. Antioxidative activities of some commercial honeys, royal jelly, and propolis. *Food Chem*, 75: 237-240.
- Park YK, MH Koo and JA Abreu, 1998. Antimicrobial activity of propolis on oral microorganisms. *Curr. Microbiol*, 36: 24–28.
- Subrahmanyam MA, 1998. Prospective randomised clinical and histological study of superficial burn wound healing with honey and silver sulfadiazine. *Burns*, 24: 157-161.